



Effectiveness of electroconvulsive therapy in Lance-Adams syndrome



Keywords:

Lance-Adams syndrome
 Posthypoxic myoclonus
 Cortical myoclonus
 EEG
 Electroconvulsive therapy
 Neuromodulation

Dear Editor,

Chronic posthypoxic myoclonus, or Lance-Adams syndrome (LAS), is a severely disabling consequence of anoxia [1]. The leading symptoms of LAS are multifocal or sometimes generalized action/intention myoclonic jerks. LAS occurs days or weeks after a brain hypoxic event from various cardiac and/or respiratory origins. Its treatment relies on antiseizure medications (ASM) but without a clear efficacy. We report the striking features of a patient with LAS, refractory to many ASM, who presented generalized seizures leading to transient decrease of myoclonus. This patient benefited from repeated electroconvulsive therapy (ECT) to reproduce generalized seizures and to decrease her myoclonus, with a functional testing follow-up using the Unified Myoclonus Rating Scale (UMRS) [2]. A written consent was signed by the patient for publication of her data.

We managed a woman with LAS for 15 years in our Epilepsy Unit. At the age of 38, she underwent a surgery for fallopian tube ligation. She presented a postoperative generalized status epilepticus complicated by a ventilator-associated pneumonia. After awakening in the intensive care unit, she displayed mainly action/intention and also tactile and auditory stimuli-sensitive positive myoclonus, over oral-face area, trunk, and limbs, mostly multifocal but also generalized. Moreover, she had lower limbs negative myoclonus which caused falls and fractures. Early brain MRI was normal, and subsequent ones showed a mild brain atrophy. Standard biologic tests were normal. Iterative standard EEG showed (poly)spikes-and-waves over frontal and central median areas (Supplementary material 1). Surface polymyographic recordings of myoclonus showed, at rest, intermittent myoclonic jerks, sometimes in doublets or triplets, with a duration from 36 to 48 ms (Supplementary material 2). During action and orthostatism, jerks' amplitude and frequency increased whereas their duration was in the same range. We also recorded synchronous negative myoclonus as electrical silences just after positive myoclonic jerks. We finally performed EEG jerk-locked back averaging that showed a premyoclonic cortical potential over the central median electrode.

The diagnosis of LAS was made. She received multiple ASM at effective dose: levetiracetam, valproate, zonisamide, topiramate, phenobarbital, and clonazepam. Despite these treatments, she still had multi-daily diffuse positive and negative myoclonic jerks interfering with all daily tasks, severely impairing her quality of life, and compelling her to use a wheelchair because she was unable to stand and walk.

During her follow-up, she reported few spontaneous generalized seizures and systematically noted at home that myoclonus decreased during the days following seizures and that she was able to stand and walk alone for short distances. We confirmed this improvement after a seizure at hospital (Supplementary material 3). We observed a decrease of all types of myoclonus, as measured by UMRS, especially the action myoclonus score: 97 before seizure vs 19 after seizure (Fig. 1A).

Because of the major alteration of her quality of life due to myoclonus, the absence of efficacy of ASM, and the improvement of myoclonus after spontaneous generalized seizures, and after the advice of our regional ethical committee, we started electroconvulsive therapy (ECT) to reproduce generalized seizures (Supplementary material 4 and 5). ECT were performed under anesthesia with etomidate (mean dosage: 17 mg) and/or propofol (mean dosage: 75 mg), and curarization with suxamethonium (mean dosage: 45 mg). For the ECT procedure, the stimulation electrodes were placed over bilateral temporal area, then a dose titration was performed to determine the seizure threshold at initial treatment, and finally a stimulus dosing of 1.5 times the seizure threshold was delivered for subsequent treatments. The stimulation protocol parameters were as follows: pulse duration 0.5 msec, frequency 40–50 Hz, stimulation duration 7–8 sec, delivered current 800–900 mA. The mean durations of electrical and clinical ECT-induced seizures were 58 and 40 sec respectively. ECT was initially performed once a week, then was spaced to every 6 weeks. No major side effects were noted. After each ECT, we noticed a decrease of myoclonus allowing a major improvement of her quality of life and autonomy. She was able to stand and walk a few meters alone or with a cane for longer distances, and to wash and eat alone. This short-term improvement was statistically significant on action myoclonus, was maximal the day after the ECT and lasted from a few days to two weeks (Fig. 1B). During the first year of ECT, the mean score of UMRS action myoclonus was 28 (± 13) between three and one day before the ECT, 18 (± 9) a few hours after the ECT, 11 (± 5) the day after the ECT, and 27 (± 11) between twelve and fifteen days after the ECT. EEG also improved after ECT. After seven years and a total of 84 ECT (in June 2022), her baseline status also improved, especially action myoclonus and autonomy for daily tasks (Fig. 1C). The mean score of UMRS action myoclonus was 33 (± 11) during the first month (ECT performed once a week), 28 (± 13) during

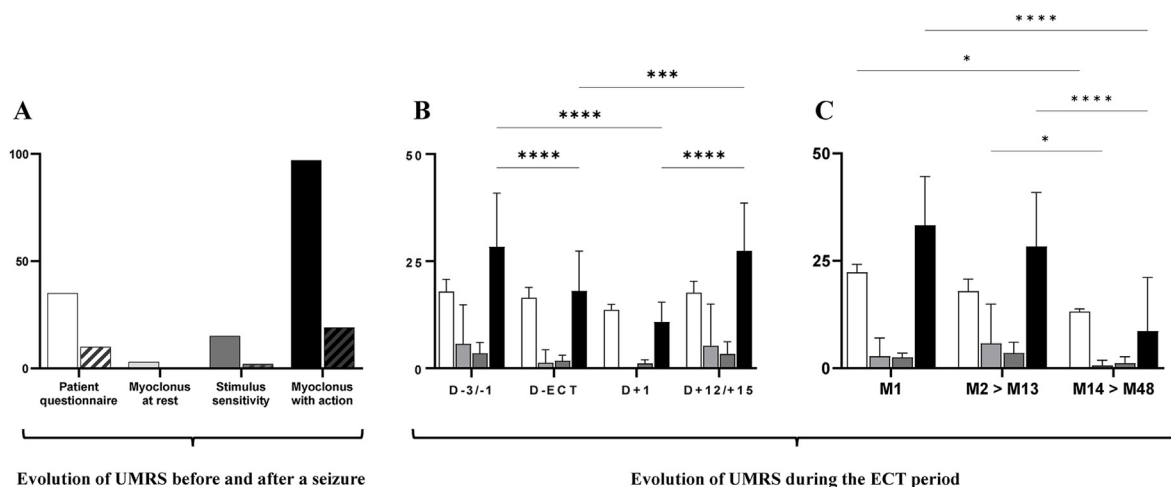


Fig. 1. Effects of seizure (A) and ECT at short- (B) and long-term (C) on the Unified Myoclonus Rating Scale.

(A) Evaluation of *Patient questionnaire* (degree of dependence in daily tasks, white), *Myoclonus at rest* (light grey), *Stimulus-induced myoclonus* (dark grey) and *Myoclonus with action* (black) sections of UMRS before (no hatch) and after (hatched) a seizure that occurred while the patient was in hospital. The decrease in UMRS was especially dramatic for the *Myoclonus with action* section. (B) Means (\pm SD) of *Patient questionnaire* (white), *Myoclonus at rest* (light grey), *Stimulus-induced myoclonus* (dark grey) and *Myoclonus with action* (black) sections of UMRS during the first year of ECT (23 ECT, performed every two weeks). D-3/-1: measures obtained between three and one day before the ECT; D-ECT: measures obtained a few hours after the ECT; D+1: measures obtained the day after the ECT; D+12/+15: measures obtained between twelve and fifteen days after the ECT. A significant decrease was only observed for the *Myoclonus with action* section, whereas only a trend to decrease was observed for other types of myoclonus. (C) Means (\pm SD) of *Patient questionnaire* (white), *Myoclonus at rest* (light grey), *Stimulus-induced myoclonus* (dark grey) and *Myoclonus with action* (black) sections of UMRS of D-3/-1 measures obtained during the first month of ECT (M1, 4 ECT, performed once a week), then the first year (M2 > M13, 23 ECT, performed every two weeks), then the next four years (M14 > M48, 31 ECT, performed every 4–6 weeks). A significant decrease was especially observed for the *Myoclonus with action* section. *: $p < 0.05$, ***: $p < 0.001$, ****: $p < 0.0001$.

the first year (ECT performed every two weeks), and $9 (\pm 12)$ during the next four years (ECT performed every four to six weeks).

To our knowledge, this is the first report of myoclonus improvement after spontaneous generalized seizures and ECT-induced seizures in LAS. The mechanism of action of ECT is poorly understood. γ -aminobutyric acid (GABA) enhancement is one of the most suggested hypotheses for the anticonvulsive theory of ECT. Increase of seizure threshold and decrease of seizure duration in patients receiving recurrent ECT may be related to an increase in the tonic GABA inhibition after repeated seizures [3–5]. The precise pathophysiology of myoclonus in LAS remains obscure and which neurons or networks are critically injured to generate myoclonus in this disease is not clearly understood since the first report by Lance and Adams in 1963 [6]. Chronic posthypoxic myoclonus may originate in cortical structures, subcortical ones, or both [1,7]. In our patient, the mainly focal distribution of myoclonic jerks that especially occurred during action/intention, the interictal epileptic activities over central electrodes on scalp EEG, the short duration of myoclonus <50 ms on polygraphic EMG recordings, and the premyoclonic EEG potential on EEG-jerk locked back averaging argued for the cortical origin of myoclonus [8]. In cortical myoclonus, abnormal GABA transmission and impaired intracortical inhibition have been suggested as a possible mechanism, in particular in primary motor cortex, explaining motor cortical hyperexcitability [9]. Electroconvulsive therapy, by reinforcing GABA transmission, as observed after spontaneous seizures, may thus represent a novel way to enhance inhibitory cortical networks in LAS. Our results obviously need to be confirmed in other patients. ECT was also suggested as therapeutic option for super-refractory status epilepticus [10]. The improvement of myoclonus after spontaneous generalized seizures and after ECT-induced generalized seizures may pave the way for further clinical and preclinical research on the still unknown pathophysiological mechanisms of LAS.

Supplementary material are available at the open access repository Zenodo (<https://doi.org/10.5281/zenodo.7620808>).

Funding source

This work received support from the “Investissements d’avenir” program ANR-10-IAIHU-06 and Fondation Assistance Publique des Hôpitaux de Paris (EPIRES – Marie Laure Merchandising). GV was supported by Fondation pour la Recherche Médicale (FRM; FDM202106013478).

Declaration of competing interest

The authors declare that they have no known competing financial interests or personal relationships that could have appeared to influence the work reported in this paper.

Acknowledgements

None.

Supplementary data

Supplementary data to this article can be found online at <https://doi.org/10.1016/j.brs.2023.03.004>.

References

- [1] Gupta HV, Caviness JN. Post-hypoxic myoclonus: current concepts, neurophysiology, and treatment. *Tremor Other Hyperkinet Mov* 2016;6:409. <https://doi.org/10.7916/D89C6XM4>.
- [2] Frucht SJ, Leurgans SU, Hallett M, Fahn S. The unified myoclonus rating Scale. *Adv Neurol* 2002;89:361–76.

- [3] Hermida AP, Glass OM, Shafi H, McDonald WM. Electroconvulsive therapy in depression : current practice and future direction. *Psychiatr Clin* 2018;41(3): 341–53. <https://doi.org/10.1016/j.psc.2018.04.001>.
- [4] Seymour J. Commentary and update on the contribution of the GABA hypothesis to understanding the mechanism of action of electroconvulsive therapy. *J ECT* 2021;37(1):4–9. <https://doi.org/10.1097/YCT.0000000000000711>.
- [5] Farrant M, Nusser Z. Variations on an inhibitory theme: phasic and tonic activation of GABA(A) receptors. *Nat Rev Neurosci* 2005;6(3):215–29. <https://doi.org/10.1038/nrn1625>.
- [6] Lance JW, Adams RD. The syndrome of intention or action myoclonus as a sequel to hypoxic encephalopathy. *Brain* 1963;86:111–36. <https://doi.org/10.1093/brain/86.1.111>.
- [7] Hallett M. Physiology of human posthypoxic myoclonus. *Mov Disord* 2000;15(Suppl 1):8–13. <https://doi.org/10.1002/mds.870150703>.
- [8] Apartis E, Vercueil L. To jerk or not to jerk: a clinical pathophysiology of myoclonus. *Rev Neurol (Paris)* 2016;172(8–9):465–76. [10.1016/j.neurol.2016.07.013](https://doi.org/10.1016/j.neurol.2016.07.013).
- [9] Mazzoni P, Jain S. Myoclonus. In: Gilman Sid, editor. *Neurobiology of disease*. Academic Press; 2007. p. 305–17. <https://doi.org/10.1016/B978-012088592-3/50032-3>.
- [10] Bayrlee A, Ganeshalingam N, Kurczewski L, Brophy GM. Treatment of super-refractory status epilepticus. *Curr Neurol Neurosci Rep* 2015;15(10):66. <https://doi.org/10.1007/s11910-015-0589-2>.

Geoffroy Vellieux

Paris Brain Institute, ICM, Inserm, CNRS, Sorbonne Université, F-75013, Paris, France

AP-HP, Epilepsy Unit, Pitié-Salpêtrière Hospital, Paris, France

Emmanuelle Apartis

Paris Brain Institute, ICM, Inserm, CNRS, Sorbonne Université, F-75013, Paris, France

AP-HP, Neurophysiology Department, Saint-Antoine Hospital, Paris, France

Vincent Degos

AP-HP, Neurosurgical Intensive Care Unit, Pitié-Salpêtrière Hospital, Paris, France

Clinical Research Group 29, Sorbonne Université, Paris, France

Philippe Fossati

Paris Brain Institute, ICM, Inserm, CNRS, Sorbonne Université, F-75013, Paris, France

AP-HP, Psychiatry Department, Pitié-Salpêtrière Hospital, Paris, France

Vincent Navarro*

Paris Brain Institute, ICM, Inserm, CNRS, Sorbonne Université, F-75013, Paris, France

AP-HP, Epilepsy Unit, Pitié-Salpêtrière Hospital, Paris, France

* Corresponding author. AP-HP, Epilepsy Unit, Pitié-Salpêtrière Hospital, 47 boulevard de l'Hôpital, 75013, Paris, France. E-mail address: vincent.navarro@aphp.fr (V. Navarro).

20 January 2023

Available online 17 March 2023